

Cryptogenic gray cutaneous lesions in Risso's dolphins (*Grampus griseus*) from La Herradura, Coquimbo, Chile: an emerging disease in calves

Marie-Francoise Van Bressem^{1*}, Macarena Bravo², Gian Paolo Sanino³

¹ Cetacean Conservation Medicine Group (CMED), Peruvian Centre for Cetacean Research (CEPEC), Museo de Delfines, Pucusana, Peru.

²The Swire Institute of Marine Science, University of Hong Kong, Hong Kong.

³Centre for Marine Mammal Research—LEVIATHAN, Santiago, Chile.

Abstract

The presence of cryptogenic gray cutaneous (CGC) lesions is reported in Risso's dolphins (*Grampus griseus*) occurring in La Herradura de Guayacán Bay and surrounding waters in the Coquimbo region, Chile, in 2011-2012. Images were examined for skin lesions, body condition and state of the dorsal fin. For epidemiological analysis, individuals were split into three categories: adults, immatures and calves. For the calf category, the number of individuals and prevalence of skin conditions were calculated separately for the right (RS) and left (LS) sides, as it was not always possible to accurately match their sides. A total of 749 adults, 44 immatures and 81 (LS) and 99 (RS) calves were photo-identified. Forty-three calves had both sides matched. CGC lesions appearing as small to very large, oval or rounded light gray lesions, sometimes in relief or ulcerated were observed on all visible body areas of 24 (LS) to 36 (RS) calves, five immatures and one adult. At least nine positive calves were neonates. In two calves the CGC lesions persisted for a minimum of 11.5 months. The health of seven to nine calves was visibly degraded. Prevalence of CGC lesions in 43 calves with both sides matched was 23.3% but varied between 29.6% and 36.4% in 81 LS and 99 RS calves, respectively. It was lower in immatures (11.4%, N= 44) and adults (0.14%, N= 749). Pollution of the bay and surrounding waters may affect the immune system and skin barrier in calves, facilitating the entry of micro-organisms and infection. [JMATE. 2018;10(2):11-20]

Keywords: Risso's dolphin, Chile, skin disease, calves, cetacean, pollution

Introduction

Skin diseases have been reported in several species of coastal small cetaceans worldwide (33, 36, 37, 41, 43-45, 50). Though most of them eventually resolve, some persist and progress, affecting large areas of the skin (10, 36, 44, 45). Along the Pacific coast of South America, cutaneous diseases of small cetaceans include tattoo skin disease, lobomycosis and lobomycosis-like disease, pale dermatitis, expansive annular lesions, focal skin disease (FSD), pale skin patches, skin lineal anomalies, and ulcerative dermatitis (36, 41, 43-45). With the exception of tattoo skin disease caused by cetacean poxviruses, and lobomycosis of fungal origin, little is known of their etiology and pathogenesis (5, 6, 48). However, anthropogenic factors such as pollution and unusual

stress may increase their severity and prevalence (34, 36, 44-46). In Chile, skin diseases have been described in a Bryde's whale (*Balaenoptera brydei*), Burmeister's porpoises (*Phocoena spinipinnis*), Chilean dolphins (*Cephalorhynchus eutropia*), common bottlenose dolphins (*Tursiops truncatus*), and Peale's dolphins (*Lagenorhynchus australis*) (36, 42, 43, 45).

Risso's dolphins (*Grampus griseus*) are stout Delphinidae less than four meters long with a bulbous head and a very tall, falcate dorsal fin. They accumulate cutaneous white scars through their lifetime and their coloration pattern varies strikingly with age (1, 3, 18). Generally, calves are unscratched, brown-gray with a yellowish, lighter colored head and belly. Immatures are dark grey and lighten while maturing (1). Scratches and tooth rakes increase with age, and older adults are almost white, covered with numerous unpigmented scars that are mainly the result of bites from conspecifics, of fights with squids on which they prey and of wounds of anthropogenic and parasitic origin (1, 3, 11, 18, 29, 30). Nineteen types of marks have been reported on the dorsal fin of *G. grampus* from the Mediterranean Sea (29). Most are long-lasting in adults and subadults allowing their reliable use for photo-identification (20, 29). Nevertheless, there are no mentions of skin diseases in any populations of this broadly distributed species.

G. griseus occurs in all habitats from coastal to oceanic with preference for mid-temperate waters of the continental shelf and slope (23). In the South-East Pacific they are found from the Equator to southern Chile (23, 31). Relatively little is known of their ecology and the threats they face in this region, but they are occasionally used for human consumption and bait in Peru (15, 40, 47). In December 1997 and January 1998, the Scientific Committee of the International

Received November 22, 2018; Accepted December 8, 2018.

Correspondence: Marie-Francoise Van Bressem

Cetacean Conservation Medicine Group (CMED), Peruvian Centre for Cetacean Research (CEPEC), Museo de Delfines, Pucusana, Peru.

Email: mfb.cmed@gmail.com



Whaling Commission conducted the most comprehensive sighting survey of cetaceans in Chilean waters. This produced 26 sighting records of *G. griseus*, ranging between 10 and 106 nautical miles (nm) to the shore, with an average of 61.3 nm, 66.7% over 40 nm and only 4.2% closer than 15 nm (12). These findings were consistent with the pelagic distribution commonly attributed to the species from sighting and stranding records (31) and stomach content (53). However, since the early 2000s groups of Risso's dolphins have also been frequently recorded in coastal waters of the Atacama and Coquimbo regions of Chile¹ (52).

In 2011-2012, groups of *G. griseus* were observed to regularly use La Herradura de Guayacán Bay (29° 58'29.8"S, 71°21' 28.7"W) and surrounding waters in the Coquimbo region, central Chile (7). During photo-identification studies inside and outside the bay, light gray cutaneous lesions were observed in several calves and neonates, prompting us to examine the macroscopic and epidemiological characteristics of this condition and to evaluate the external health of the affected individuals.

Material & Methods

Study Area and surveys: The study area covered La Herradura Bay and the adjacent coast from Punta Saliente (29°59'58.5"S, 71°24'58.0"W) to Punta Tortuga (29°56'02.1"S, 71°20'33.3"W) (Figure 1). Located in the Coquimbo Region, along the north-central coast of Chile, La Herradura de Guayacán Bay (referred as 'La Herradura') is a small and shallow (20 to 60 m) area, measuring about 3.3 km² and protected from the ocean by a 70 m wide entrance channel (4). It is part of a highly productive coastal area (38).

A total of 63 surveys were carried out from April 2011 to May 2012 using a 7 meter long and 1.5 meter high boat with a 25 horsepower outboard engine, with sea states ranging 1-3 of the Beaufort scale. Inside La Herradura, 16 boat surveys were conducted after the dolphins were detected through shore-based scans. Outside the bay, 47 surveys were carried out with a total of 13 encounters (7). The boat approached the dolphins at a steady speed (approximately 2 knots inside the bay and 5 knots outside the bay) parallel to the group. Photographs of dorsal fins and upper bodies were collected using a DSLR Nikon D90 camera with a 70-300 mm zoom lens (7).

Dolphins and Photo-identification: The population structure of *G. griseus* has not yet been assessed in La Herradura and surrounding waters. However, for this

contribution we assume that the observed groups are part of a single population. The group size per sighting record ranged from 4 to 143 individuals. Inside the bay the mean and median size of the groups was 63 (SD= 45.3) and 46 individuals, respectively. Most groups (87.5%) included calves and their main activity was milling. Outside the bay, groups had a mean and a median size of 20 (SD= 19.5) and 16 individuals, respectively and only 38.5% of them had calves (7). Digital images of the dorsal fin were used to identify individuals according to their marks, nicks and notches. Images were processed using the software DISCOVERY to enhance brightness, sharpness and contrast, as described by Gailey and Karczmarski (14). Image quality was rated according to sharpness and light exposure as well as to the percentage of the dorsal fin captured in the picture and its' angle, following the 1-100 rating scale of Karczmarski *et al.* (24). Only good quality images ($Q \geq 75$) were used for the identification of individuals. Calves were identified through their regular association with an adult dolphin, presumably the mother. In some cases, calves photographed alone were identified using long-lasting skin marks and/or nicks in their dorsal fin, as described (29).

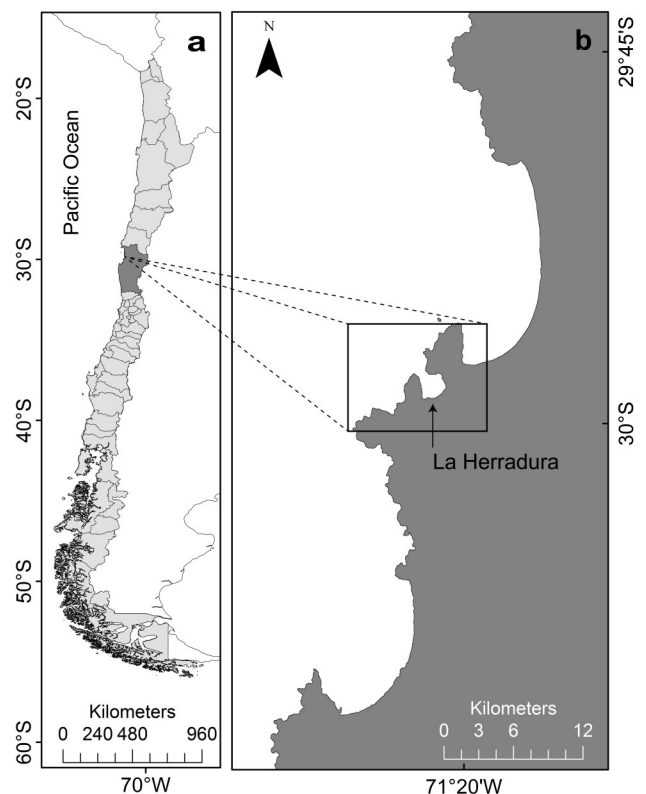


Figure 1. (a) Map of Chile with the Coquimbo region in dark grey. (b) La Herradura de Guayacán bay (arrow) and the study area (insert).

Footnote: ¹A. Canepa pers. com. to GPS 2004).

Data collection and analysis: Good to medium ($Q \geq 50$) quality images of the PI-catalog were searched for cryptogenic gray cutaneous (CGC) lesions. Images of suspected positive dolphins were extracted and further analysed. The gross external characteristics of the lesions were examined in each dolphin, including their form, number, size and distribution. To estimate the lesions' relative size we considered the eye, blowhole and dorsal fin of each dolphin as visual references (36). 'Small-sized' corresponded to lesions affecting areas smaller than half of the eye or blowhole diameter; 'medium-sized' were those with a diameter smaller than twice the eye or blowhole diameter, or up to a quarter of dorsal fin base length (DFBL); 'large-sized' were up to half of the DFBL or 4 times the diameter of the blowhole or eye. Bigger lesions were considered as 'very large' (36). Progression, persistence and regression of the lesions were evaluated in dolphins with between year re-captures. To assess the external health of the dolphins with CGC lesions, we developed a health index that integrated the body condition, the state of the dorsal fin and the presence of other skin anomalies, including ulcers, orange patches and FSD (32, 36, 45). The body condition was considered abnormal when the ribs were visible and/or a concave depression was seen behind the head (9). Orange patches are orange or rusty-colored marks that may coalesce to form larger blotches and are likely caused by the colonization of the skin by epidermal diatoms (28, 45). Their presence over several areas of the body may reflect an insufficient development of the skin barrier (28). FSD is characterized by clusters of small, round or oval light or dark skin lesions, not attributable to injuries or scars (36) and which resemble the spotted lesions described by Hart *et al.* (8). Cutaneous ulcers are defined as open sores, caused by a break in the skin that does not heal. Abnormal dorsal fins may be collapsed, bent or disfigured (2, 49). The external health of a dolphin was considered 'degraded' when large and very large CGC lesions were observed together with at least one of the following indicators: cutaneous ulcers, abnormal dorsal fin, extensive orange patches, FSD or visible loss of fat thickness; or when medium to large lesions occurred with at least two of the health indicators.

For epidemiological analysis, individuals were split into three categories: adults (A), immatures (I) and calves including neonates (C). Adults are large light grey dolphins, often heavily scarred with a bulbous head and a vertical crease along the melon surface (1, 20). Immatures are smaller than adults, have a darker color

and limited to moderate scarring. They include the juvenile and sub-adult categories described by Hartman *et al.* (20). Calves and neonates have a small size and a dark gray color and are regularly sighted in the proximity of the same adult (1, 20). Neonates are characterized by the presence of fetal folds and a yellowish colour of the head (19). For the (C) category, the number of individuals and prevalence of skin conditions were counted separately for the right (RS) and left side (LS), as it was not always possible to accurately match their sides when photographed without their mothers.

Results

A total of 749 adults, 44 immatures and 81 LS and 99 RS calves were photo-identified during the study (7). Forty-three calves had both sides matched. A skin disease characterized by irregular, oval or rounded light gray lesions that were sometimes slightly in relief or ulcerated (Figure 2a,b,c,d) was observed in 24 (LS) and 36 (RS) calves, five immatures and one adult, inside and outside the bay. Nine (LS) and 11 (RS) positive calves were estimated to be neonates (Figure 2a,b,c). The lesions were observed on all visible body areas and varied in size from small to very large (Figures 2, 3) in all ontogenetic categories. Between 11 (LS) and 18 (RS) calves of whom three (498C, 24C and 422C) were neonates had very large lesions. In 498C they seemed superinfected and had a velvety appearance (Figure 2c). In three other calves (33C, Cría 16 and 394C) the CGC lesions had a stippled pattern reminiscent of tattoo skin disease (Figure 2d). Nine (LS) and 11 (RS) positive calves were re-identified during the study period. In two of them (157C and 10C), the large and very large skin lesions first observed in May 2011, persisted for at least 11.5 months though apparently fading in April 2012 (Figure 3). The external health of seven (RS) to nine (LS) positive calves was considered degraded (Table 1). The most notorious case, calf 492C, had medium to very large CGC lesions on both sides and a slightly bent dorsal fin in May 2011 (Figure 4a). In November 2011, the dorsal fin had collapsed (Figure 4b), ulcers had developed on two CGC lesions and orange patches were observed on most visible body areas (Table 1). A large ulcer was also seen on the rostrum of neonate 498C. Details for all calves and neonates with an altered health are given in Table 1. The external health of the six other positive non-calf dolphins (one adult, five immatures) was considered normal. Minimal prevalence of CGC lesions in 43 calves with both sides matched was 23.3%



Figure 2. *Grampus griseus*. (a) A very large rounded, light gray lesion in neonate 422C on 23 April 2012; (b) Medium and large, ulcerated skin lesions in neonate 749C in May 2011; (c) Large and very large light gray skin lesions with a velvety appearance on the back and flank of neonate 498C in May 2011; (d) Large and very large cutaneous lesions resembling tattoo skin disease in calf 16C on 23 July 2011. Photographs reproduced with permission from authors.



Figure 3. Large and very large light gray cutaneous lesions in calf 157C in May 2011 (a) and April 2012 (b). The lesions seem to be fading in 2012. Photographs reproduced with permission from authors.



Figure 4. Medium to very large light gray cutaneous lesions in calf 492C in May (a) and November 2011 (b). During that six month period, skin lesions had developed on the dorsal fin that had completely bent. Photographs reproduced with permission from authors.

but varied between 29.6% and 36.4% in 81 LS and 99 RS calves respectively. It was lower in immatures (11.4%, N= 44), significantly by Z-score test when LS ($z= 2.311$; $p= 0.021$) and RS ($z= 3.051$; $p= 0.0023$) calves were considered, but not when only calves with both sides matched were taken into consideration (two-tailed Z-score test, $z= 1.468$; $p= 0.142$). The lowest prevalence was seen in adults (0.14%, N= 749).

Discussion

During this study, a skin disorder characterized by oval or rounded, light gray lesions was observed in *G. griseus* free-ranging in La Herradura and surrounding waters, in the Coquimbo region, Chile, between April 2011 and May 2012. Similar lesions were also seen in some calves and immatures photographed in the bay in 2007-2010². To our knowledge this is the first description of a cutaneous disease in this species. CGC lesions have not been observed during other sightings of this species along the coast of Chile even close to the study area, with the most recent sighting record dating from March 2018 at 10 nm Northwest from La Herradura bay (29°50'12.12"S, 71°29'12.12"W)³. In other small cetaceans, cutaneous disorders most closely resembling the CGC lesions are the expansive annular lesions seen in a false killer whale calf (*Pseudorca crassidens*) from southern Brazil and in a Chilean dolphin calf from northern Chile, the pale dermatitis observed in Guiana dolphins (*Sotalia guianensis*) from Sepetiba and Paranagua Bays, Brazil, the pale skin patches photographed in *C. eutropia* and *L. australis* from the Añihué Reserve, Chile and the whitish marks identified in *T. truncatus* from the Moray Firth, Scotland (36, 45, 51). In three calves the stippled pattern of some CGC lesions resembled that of tattoo skin disease, a poxvirus infection affecting several species of cetaceans worldwide, but rarely found in young calves and neonates (33, 36, 42). However, the role of poxviruses in the development of the CGC lesions is unknown. Further research including histopathology, electron microscopy and molecular studies are necessary to determine the etiology of this disease.

During the present study the CGC lesions were often observed in calves and immatures but less frequently in adults. The light gray color of the latter and their sometimes extensive scarring could have reduced the detection of CGC lesions. However, it is possible that the CGC lesions resolved as calves and immatures grew and their skin matured, as suggested by

the fading appearance of some lesions in two calves re-sighted after 11.5 months. The presence of large and very large CGC lesions in neonates indicates that the disease started very early in life. La Herradura Bay and neighboring waters are biologically and chemically polluted by human activities, including toxic spills and ore tailing discharge by mining companies, and the release of municipal wastewaters directly into the ocean (21, 22, 26, 27). The bay is home to the most important iron landing port in Chile's IV Region, a fish factory, algae and shellfish farming facilities and a yacht club. In addition, fishing boats and large vessels servicing the local iron company regularly transit through these waters. Finally, mining waste has been disposed north of the study area, along the coast and in the ocean of the Atacama region since 1978, at rates sometimes exceeding 4700 m³ per day despite the fact that its health effects on humans, cetaceans and other marine life are unknown (39). Pollutants present in the bay and surrounding waters may alter the immature skin barrier in calves, facilitating the entry of micro-organisms and subsequent infection (28). Besides, they may also affect their fragile immune system, thus further favoring the development of infectious diseases, as described in other odontocete species (16, 17, 34). This possibility should be further explored. Our findings highlight the importance of applying the precautionary principle and to prevent all mining waste and untreated wastewaters from accessing the sea.

Miscellaneous skin lesions occur in odontocete calves worldwide, with prevalence levels varying markedly between them (25, 33, 35, 36, 43, 45, 51). Although some skin conditions like the orange marks seem of little concern, others like expansive annular lesions, granulomatous diseases (including lobomycosis) and some ulcerative cutaneous conditions may have a negative impact on the general health and survival of the affected calves (10, 13, 25, 35, 45). The emergence of CGC lesions in calves of Risso's dolphins from Northern Chile is worrisome and should be further monitored. Whenever possible samples should be collected for histology and microbiology to determine the etiology of CGC and examine its zoonotical potential, especially considering the density of human activities in this area. The occurrence of such lesions should also be investigated in other species of small cetaceans from this and other Chilean regions, such as southern Huasco Port, a mining waste disposal area in the Atacama region.

footnote ² O. Yates, personal communication
³ GP Sanino, unpublished data



Ind	Age	Side	CGC lesions			Health index				Bay Location
			Number	Size	Minimal Duration	Dorsal fin	Orange patches	Skin ulcers	Focal skin disease	
14C	Neo	LS	3	Medium to large	Unknown	Normal	No	No	Yes	OUT
103/74C	Neo	Both	4-6	Medium to large	Unknown	Normal	No	Yes	No	INS
268C	Neo	LS	>10	Small to large	6 months	Normal	Yes	Possibly	Possibly	INS
498C	Neo	RS	3	Medium to very large	Unknown	Normal	No	Yes	No	INS
749C	Neo	LS	6	Medium to large	Unknown	Normal	Yes	Yes	No	INS
7C	Calf	LS	6	Small to medium	Unknown	Normal	Yes	No	Yes	INS
101C	Calf	Both	10	Small to very large	Unknown	Nick	Yes	No	Yes	INS
348C	Calf	RS	>10	Small to large	2 weeks	Deep cut in leading edge, nick in trailing edge	No	No	No	Both
365C	Calf	RS	3	Medium	7 months	Normal	Yes	No	Yes	INS
492C	Calf	Both	8	Medium to very large	6 months	Bent	Yes	Yes	No	INS
593C	Calf	LS	>10	Small to very large	Unknown	Normal	No	No	Possibly	INS
SM4C	Calf	LS	6	Medium to large	Unknown	Normal	No	No	Yes	INS
SM7C	Calf	RS	7	Very large	Unknown	Normal	Yes	No	Possibly	INS

Table 1: Details on Risso's dolphins (*Grampus griseus*) calves and neonates affected by cryptogenic gray cutaneous (CGC) lesions and whose health condition was considered 'altered'. All individuals (Ind) were photographed in April 2011 to May 2012 in La Herradura de Guayacán Bay and surrounding waters, Chile. Dolphin side is LS-left, RS-right. Bay location: INS=inside the Bay; OUT= outside the Bay. Age is designated as neonate (Neo) or calf.

Acknowledgments

We kindly thank Dr Koen Van Waerebeek for his opinion on the skin lesions and for comments on the manuscript, Oliver Yates for revising some of his pictures of *G. griseus* in La Herradura Bay for the presence of skin lesions, Ben Burville for editing the manuscript, three anonymous reviewers for their constructive comments on the manuscript, the Facultad de Ciencias del Mar de la Universidad Católica del Norte for lending their boat for the surveys and The Swire Institute of Marine Science. We also kindly acknowledge boat captain Freddy González for his help during the surveys.

References

1. Baird RW. Risso's dolphin. In: *Encyclopedia of marine mammals* (2nd.) edited by Perrin WF, Würsig B, Thewissen JGM. Academic Press, Amsterdam, pp. 975-976. 2009.
2. Baird RW, Gorgone AM. False Killer Whale Dorsal Fin Disfigurements as a Possible Indicator of Long-Line Fishery Interactions in Hawaiian Waters. *Pacific Science* 59(4): 593–601. 2005. <https://doi.org/10.1353/psc.2005.0042>.
3. Bearzi G, Reeves RR, Remonato E, Pierantonio N, Airoidi S. Risso's dolphin *Grampus griseus* in the Mediterranean Sea. *Mammalian Biology* 76 (4):385-400. 2011. <https://doi.org/10.1016/j.mambio.2010.06.003>.
4. Berríos M, Olivares J. Granulometric characterization and organic carbon content of surface marine sediments, in the bays system of the IV Región. Coquimbo. *Ciencia y Tecnología del Mar* 19:37-45. 1996.
5. Blacklaws BA, Gajda AM, Tippelt S, Jepson PD, Deaville R, Van Bresseem M-F. *et al.* Molecular characterization of poxviruses associated with tattoo skin lesions in UK cetaceans. *PLoS ONE* 8(8):e71734. 2013. <https://doi.org/10.1371/journal.pone.0071734>.
6. Bracht AJ, Brudek RL, Ewing RY, Manire CA, Burek KA, Rosa C, *et al.* Genetic identification of novel poxviruses of cetaceans and pinnipeds. *Archives of Virology* 151(3):423–438. 2006.
7. Bravo M. Risso's dolphins of La Herradura, Coquimbo, Chile (MSc thesis) The University of Hong Kong, Hong Kong. 2013. <http://hub.hku.hk/handle/10722/183062>.
8. Hart LB, Rotstein DS, Wells RS, Allen J, Barleycorn A, Balmer BC, *et al.* Skin lesions on common bottlenose dolphins (*Tursiops truncatus*) from three sites in the Northwest Atlantic, USA. *PLoS ONE* 7(3):e33081. 2012. <https://doi.org/10.1371/journal.pone.0033081>.
9. Clegg ILK, Borger-Turner JL, Eskelinen HC, Well C. The development of a welfare assessment index for captive bottlenose dolphins (*Tursiops truncatus*). *Animal Welfare* 24 (3):267-282. 2015. <https://doi.org/10.7120/09627286.24.3.267>.
10. Daura-Jorge FG, Simões-Lopes PC. Lobomycosis like disease in wild bottlenose dolphins *Tursiops truncatus* of Laguna, southern Brazil: monitoring of a progressive case. *Diseases of Aquatic Organisms* 93 (2):163-170. 2011.
11. de Boer MN, Eisfeld S, M Simmonds. The fine-scale habitat use of Risso's dolphins (*Grampus griseus*) off Bardsey Island, Cardigan Bay (UK). *European Cetacean Society Special Publication Series*, Galway, Ireland, 54. 2013. https://www.researchgate.net/publication/261215544_The_fine-scale_habitat_use_of_Risso's_dolphins_Grampus_griseus_off_Bardsey_Island_Cardigan_Bay_UK.
12. Findlay K, Pitman R, Tsurui T, Sakai K, Ensor P, Iwakami H, *et al.* "1997/1998 IWC-Southern Ocean Whale and Ecosystem Research (IWC-SOWER) Blue Whale Cruise, Chile." Final Report of the third IWC Blue Whale Cruise of the International Whaling Commission SOWER program. 39pp. 1998. https://www.researchgate.net/publication/331531582_IWC-SOUTHERN_OCEAN_WHALE_AND_ECOSYSTEM_RESEARCH_IWC-SOWER_BLUE_WHALE_CRUISE_CHILE/stats.
13. Fiorito CD, Bentancor A, Lombardo D, Bertellotti M. *Erysipelothrix rhusiopathiae* isolated from gull-inflicted wounds in southern right whale calves. *Diseases of Aquatic Organisms* 121(1): 67-73. 2016. DOI: <https://doi.org/10.3354/dao03041>.
14. Gailey G, Karczmarski L. Discovery: Photo-identification data-management system for individually recognizable animals. Beta release version; copyright Gailey & Karczmarski 2011. Software available from the Cetacean Behavioural Ecology Lab, The Swire Institute of Marine Science, The University of Hong Kong. 2012.
15. Garcia-Godos IG, Cardich C. First mass stranding of Risso's dolphins (*Grampus griseus*) in Peru and its destiny as food and bait. *Marine Biodiversity*



- Records, doi:10.1017/S1755267209991084; Vol. 3 e3. 2010.
16. Hall AJ, Hugunin K, Deaville R, Law RJ, Allchin CR, Jepson PD. The risk of infection from polychlorinated biphenyl exposure in harbor porpoise (*Phocoena phocoena*) - a case-control approach. *Environmental Health Perspectives* 114(5):704–711. 2006.
 17. Hall AJ, McConnell BJ, Schwacke LH, Ylitalo GM, Williams R, Rowles TK. Predicting the effects of polychlorinated biphenyls on cetacean populations through impacts on immunity and calf survival. *Environmental Pollution*. 233:407-418. <https://doi.org/10.1016/j.envpol.2017.10.074> 2018.
 18. Hartman KL, Visser F, Hendriks AJE. Social structure of Risso's dolphins (*Grampus griseus*) at the Azores: a stratified community based on highly associated social units. *Canadian Journal of Zoology* 86(4):294-306. 2008. <https://doi.org/10.1139/Z07-138>.
 19. Hartman KL, Fernandez M, Azevedo JMN. Spatial segregation of calving and nursing Risso's dolphins (*Grampus griseus*) in the Azores, and its conservation implications. *Marine Biology* 161:1419–1428. 2014. <https://doi.org/10.1007/s00227-014-2430-x>.
 20. Hartman KL, Wittich A, Cai JJ, Van der Meulen FH, Azevedo JMN. Estimating the age of Risso's dolphins (*Grampus griseus*) based on skin appearance. *Journal of Mammalogy* 97(2):490-502. 2016. <https://doi.org/10.1093/jmammal/gyv193>.
 21. Inda J, Bakulic Y, Cortes-Monroy J, Villalón G. "Heavy metals in *Xanthochorus cassidiformis* extracted in Coquimbo bays, La Herradura y Tongoy, Chile" Facultad de Ciencias del Mar. Universidad Católica del Norte. *Serie Ocasional* 2:93-98. 1993.
 22. Inda J, Trucco R, Cuturrufo G, Maltés O, Fernández ML, Berríos M, et al. "Environmental Impact Study at the shipment port of iron ore belonging to Compañía Minera del Pacífico S.A. in Bahía La Herradura de Guayacán, Coquimbo. IV Región" Términos de referencia propuestos, Estudio de Línea Base Primera Etapa. Universidad Católica del Norte. 1995. <http://www.cona.cl/descargas/Up%20to%20May%202002%20-%20Alfabeticamente.pdf>.
 23. Jefferson TA, Weir CR, Anderson RC, Ballance LT, Kenney RD, Kiszka JJ. Global distribution of Risso's dolphin *Grampus griseus*: a review and critical evaluation. *Mammal Review* 44(1):56–68. 2014. <https://doi.org/10.1111/mam.12008>.
 24. Karczmarski L, Würsig B, Gailey GA, Larson KW, Vanderlip C. Spinner dolphins in a remote Hawaiian atoll: social grouping and population structure. *Behavioral Ecology* 16(4):675-685. 2005. <https://doi.org/10.1093/beheco/ari028>.
 25. Kiszka J, Van Bressem MF, Pusineri C. Lobomycosis-like disease and other skin conditions in Indo-Pacific bottlenose dolphins *Tursiops aduncus* from the Indian Ocean. *Diseases of Aquatic Organisms* 842(2):151–157. 2009. <https://doi.org/10.3354/dao02037>.
 26. Larrain S, Schaeffer C. (ed). Conflicts over water in Chile: Between human rights and market rules. Pp 60, Santiago: Chile Sustentable (online report). 2010. www.chilesustentable.net/wp.../Conflicts-over-Water-in-Chile.pdf.
 27. López A, Inda J. "Bioassays of sediment elutriates from Coquimbo and La Herradura de Guayacán bays on sperm cells of *Arbacia spatuligera* (Echinodermata: Arbacioidea) and their influence on the fertilization capacity. Libro resumen XX Congreso de Ciencias del Mar. Concepción. Pág. 146. 2000. [http://www.schm.cl/congresos/PDF%20Congresos/\(20\)%20XX%20Jornadas%20de%20Ciencias%20del%20Mar.pdf](http://www.schm.cl/congresos/PDF%20Congresos/(20)%20XX%20Jornadas%20de%20Ciencias%20del%20Mar.pdf).
 28. Maldini D, Riggan JL, Cechetti A, Cotter MP. Prevalence of epidermal conditions in California coastal bottlenose dolphins (*Tursiops truncatus*) in Monterey Bay. *Ambio* 39(7):455-62. 2010.
 29. Mariani M, Miragliuolo A, Mussi B, Russo GF, Ardizzone G, Pace DS. Analysis of the natural markings of Risso's dolphins (*Grampus griseus*) in the central Mediterranean Sea. *Journal of Mammalogy* 97(6):1512-1524. 2016. doi: 10.1007/s13280-010-0066-8.
 30. McLeod CD. Intraspecific scarring in odontocete cetaceans: an indicator of male 'quality' in aggressive social interactions? *Journal of Zoology* 244(1):71-77. 1998. DOI: 10.1111/j.1469-7998.1998.tb00008.x.
 31. Olavarria C, Aguayo-Lobo A, Bernal R. Distribution of the Risso's dolphin (*Grampus griseus*, Cuvier 1812) in Chilean waters. *Revista de Biología Marina y Oceanografía* 36(1):111-116. 2001. <http://dx.doi.org/10.4067/S0718-19572001000100011>.



32. Pettis HM, Rolland RM, Hamilton PK, Knowlton AR, Burgess EA, Kraus SD. Body condition changes arising from natural factors and fishing gear entanglements in North Atlantic right whales *Eubalaena glacialis*. *Endangered Species Research* 32:237-249. 2017. doi.org/10.3354/esr00800.
33. Powell SN, Wallen MM, Bansal S, Mann J. Epidemiological investigation of tattoo-like skin lesions among bottlenose dolphins in Shark Bay, Australia. *Science of the Total Environment* 15: 630:774-780. 2018. doi: 10.1016/j.scitotenv. 2018.02.202.
34. Reif JS, Peden-Adams MM, Romano TA, Rice CD, Fair PA, Bossart GD. Immune dysfunction in Atlantic bottlenose dolphins (*Tursiops truncatus*) with lobomycosis. *Medical Mycology* 47(2): 125-135. 2009. doi:10.1080/13693780802178493.
35. Riggin JL, Maldini D. Photographic case studies of skin conditions in wild-ranging bottlenose dolphin (*Tursiops truncatus*) calves. *Journal of Marine Animals and Their Ecology* 3(1):5-9. 2010.
36. Sanino, GPS, Van BresseM M-F, Van Waerebeek K, Pozo N. Skin disorders of coastal dolphins at Añihue Reserve, Chilean Patagonia: a matter of concern. *Boletín del Museo Nacional de Historia Natural, Chile* 63:127-158. 2014.
37. Simões-Lopes PC, Paula GS, Xavier FM, Scaramelo AC. First case of lobomycosis in a bottlenose dolphin from southern Brazil. *Marine Mammal Science* 9:329-331. 1993. https://doi.org/10.1111/j.1748-7692.1993.tb00462.x.
38. Shaffer G, Salinas S, Pizarro O, Vega A, Hormazabal S. Currents in the deep ocean off Chile (30°S). *Deep-Sea Research Part I* 42(4): 25-436. 1995.
39. SNIFA. Sistema Nacional de Información de Fiscalización Ambiental. Available from <http://snifa.sma.gob.cl/v2/Sancionatorio/Ficha/1667>. 2018. Accessed 10 Nov 2018.
40. Tenicela MV. Accidental capture of a Risso's dolphin, *Grampus griseus* (Cuvier, 1812) (Cetacea, Delphinidae), in Pisco, Peru. *Publicaciones del Museo de Historia Natural, Universidad Nacional Mayor de San Marcos (A)* 48,1-5. 1994.
41. Van BresseM M-F, Van Waerebeek K. Epidemiology of poxvirus in small cetaceans from the eastern South Pacific. *Marine Mammal Science* 12:371-382. 1996. https://doi.org/10.1111/j.1748-7692.1996.tb00590.x.
42. Van BresseM M-F, Waerebeek KV, Aznar FJ, Raga JA, Jepson PD, Duignan PD, et al. Epidemiological pattern of tattoo skin disease: a potential general health indicator for cetaceans. *Diseases of Aquatic Organisms* 85(3): 225-237. 2009. https://doi.org/10.3354/dao02080.
43. Van BresseM MF, Van Waerebeek K, Reyes JC, Félix F, Echegaray M, Siciliano S, et al. A preliminary overview of skin and skeletal diseases and traumata in small cetaceans from South American waters. *The Latin American Journal of Aquatic Mammals* 6(1):7-42. 2007. http://dx.doi.org/10.5597/lajam00108.
44. Van BresseM MF, Simões-Lopes PC, Félix F, Kiszka JJ, et al. Epidemiology of lobomycosis-like disease in bottlenose dolphins *Tursiops* spp. from South America and southern Africa. *Diseases of Aquatic Organisms* 117(11):59-75. 2015. https://doi.org/10.3354/dao02932.
45. Van BresseM M-F, Flach, L, Reyes, JC, Echegaray M, Santos M, Vididi F, et al. Epidemiological characteristics of skin disorders in cetaceans from South American waters. *Latin American Journal of Aquatic Mammals* 10(1):20-32. 2015. https://doi.org/10.3354/dao02932.
46. Van BresseM MF, Van Waerebeek K, Duignan PJ. Epidemiology of tattoo skin disease in captive common bottlenose dolphins (*Tursiops truncatus*): Are males more vulnerable than females? *Journal of Applied Animal Welfare Science* 21(4): 305-315. doi: 10.1080/10888705.2017.1421076. 2018. DOI: 10.1080/10888705.2017.1421076.
47. Van Waerebeek K, Reyes JC, Luscombe A. Revisión de la distribución de pequeños cetáceos frente a Perú. In: *Recursos y dinámica del sistema de afloramiento Peruano*, edited by Halzwedel H. and Landa A. Instituto del Mar del Peru, Callao. pp. 345-351. 1988.
48. Vilela R, Bossart GD, St. Leger JA, Dalton LM, Reif JS, Schaefer AM, et al. Cutaneous granulomas in dolphins caused by novel uncultivated *Paracoccidioides brasiliensis*. *Emerging Infectious Diseases* 22(12):2063–2069. 2016. https://dx.doi.org/10.3201/eid2212.160860.
49. Visser IN. Prolific body scars and collapsing dorsal fins on killer whales (*Orcinus orca*) in New Zealand waters. *Aquatic Mammals* 24(2):71-81. 1998.



50. Wilson B, Thompson PM, Hammond PS. Skin lesions and physical deformities in bottlenose dolphins in the Moray Firth: population prevalence and age-sex differences. *Ambio* 26(4): 243-247. 1997.
51. Wilson B, Arnold H, Bearzi G, Fortuna CM, Gaspar R, Ingram S, *et al.* Epidermal diseases in bottlenose dolphins: impacts of natural and anthropogenic factors. *Proceedings of the Royal Society B*. 266(1423):1077-1083. 1999.
52. Yates O, Pérez MJ, Moraga R. Seasonal presence and habitat use of Risso's dolphin, *Grampus griseus* in coastal waters of the central north coast (Coquimbo Region) of Chile. Document presented to the VII meeting of the Latin American Society of Specialists in Aquatic Mammals. 2008. <https://www.dropbox.com/s/fyb38vulf4bsy5g/13rt.pdf>.
53. Yates O, Palavecino-Sepúlveda P. On the stomach contents of a Risso's dolphin (*Grampus griseus*) from Chile, Southeast Pacific. *Latin American Journal of Aquatic Mammals* 9(2):171-173. <http://dx.doi.org/10.5597/lajam00185>. 2011.

